

# PRE AND POST- OPERATIVE ELECTROCOCHLEOGRAPHY IN COCHLEAR IMPLANT CASES - A STUDY TO PRESERVE RESIDUAL HEARING

**Authors:** Sumit Maheshwari (1), Neha Gupta (1), Neeraj Sainy (1), Ujjwal Mehrotra(2), Rudresh Sharma(3), Rohit Mehrotra\* (4)

**Authors Affiliations:** (1) Fellow (2) Intern (3) Audiologist (4) Professor & Director- Mehrotra ENT Hospital Kanpur

## ABSTRACT

### INTRODUCTION

Electrocochleography (ECochG) is an electrophysiological technique that records electrical potentials generated by different components of the inner ear and peripheral cochlear nerve in response to acoustic stimulation. Electrical evoked potential has been long used in cochlear implant to record the neural responses during intra or post-surgery. During cochlear implant electrically evoked compound action potential(E-CAP) or neural response telemetry (NRT) test used to measure the neural responses. Historically, ECochG found its main application in the diagnostic evaluation of Meniere's disease. However, in the last decade, the focus has shifted towards cochlear implantation (CI).

### MATERIAL AND METHOD

The aim of the study is to measure residual hearing in pre and post operative cochlear implant patients using electrocochleography.

With the help of ASSR and ECochG test it could be identified that residual hearing is preserved or not. Less traumatic CI electrode array design and the use of "soft surgery" techniques allow for the preservation of residual low-frequency acoustic hearing. In patients with residual hearing after CI, combined electric and acoustic stimulation has resulted in improved hearing and speech outcomes.

## CONCLUSION

Preservation of acoustic hearing allows individuals with CIs to take advantage of periodicity, commonly referred to as voice pitch, and temporal fine structure, offering improved spectral resolution and supports in speech intelligibility better understanding in CI users. Pre implant and Post implant electrocochleography results were compared and evaluated. Comparison was made by comparing of pre and post implant peak and wave morphology, Summation Potential (SP) /Action Potential(AP) Area ratio and SP/AP Amplitude ratio.

### Keywords

Meniere's disease, Soft surgery, Residual hearing.

### INTRODUCTION

Electrocochleography (ECochG) is an electrophysiological technique that records electrical potentials generated by different components of the inner ear and peripheral cochlear nerve in response to acoustic stimulation. ECochG cochlear potential are 1-(CM) Cochlear Microphonics (AC) alternating current which is generated from the OHC (Outer Hair cells) and organ of corti (Sellick & Russell, 1980). 2- Summation Potential (SP), DC (direct current) source is not clear yet, but it's thought to arise from primarily by the IHC (Dallos, 1973). Electrical evoked potential has been long used in cochlear implant to record the neural responses during intra or post-surgery. During cochlear implant E-

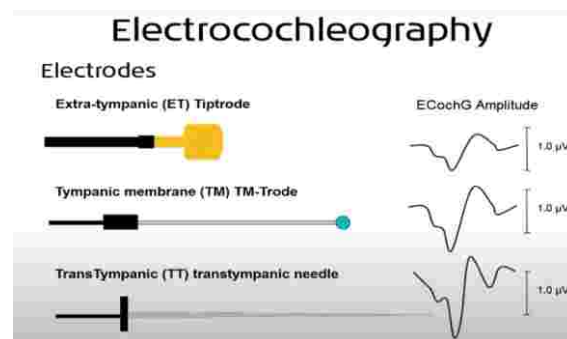
CAP or NRT test used to performed to measure the neural responses. Historically, ECoG found its main application in the diagnostic evaluation of Meniere's disease (MD). However, in the last decade, the focus has shifted towards cochlear implantation (CI). Less traumatic CI electrode array design and the use of “soft surgery” techniques allow for the preservation of residual low-frequency acoustic hearing. In patients with residual hearing after CI, combined electric and acoustic stimulation has resulted in improved hearing and speech outcomes. The importance of low-frequency hearing in the implanted ear has been well-documented in earlier studies. Preservation of acoustic hearing allows individuals with CIs to take advantage of periodicity, commonly referred to as voice pitch, and temporal fine structure, offering improved spectral resolution and supports in speech intelligibility better understanding in CI users.

## AIM

The aim of the study is to measure residual hearing in pre and post operative cochlear implant patients using electrocochleography.

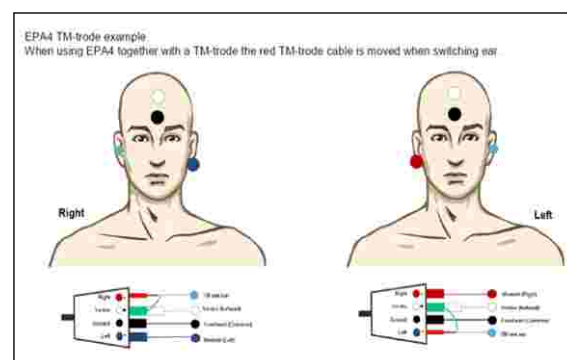
## MATERIAL AND METHODS

Study was carried out at late Dr S N Mehrotra Charitable ENT foundation from January to June 2022. Electrocochleography test was performed 24 hrs before and after cochlear implantation. Electrodes placed extracochlear on the tympanic membrane. Pre operative and post operative ECoG test was done in 40 children. Study was done by collecting data through fully completed clinical records and file was reviewed to see the residual hearing. Children who have minimum level of responses at 90, 100, 110 dBnHL at 500 KHz, 1000 khz, 2000 khz and 4000 khz are only included. Children who had no response at any of the frequency region at maximum level of stimulus 110 dBnHL were not included in the study. ABR and ASSR was done using standard instrument Interacoustic Eclipse EP -25 dual channel 1 month prior to the surgery. ECoG test was performed before surgery.



## ECoHG test was done following protocols: -

PARAMETERS	SUGGESTION
Transducer	Insert phone RadioearIP- 30
Electrode	TM Electrode (Lilly T-M Wick Electrode)
Stimulus type	Tone Burst 500k, 1k, 2k, 4k
Stimulus rate	71/sec.
Intensity	95 -115dBnHL
Recording sweeps	1500
Filter	High pass 10 Hz 6/oct, Low pass-5000 Hz



Before performing the ECoG Test otoscopic examination was done for the confirmation of wax clearance and structure of the ear canal. Ear canal and surface area of electrode placement was cleaned with the Nu-prep gel. Lilly T-M Wick Electrode was used. Length of the ear canal was measured and electrode was kept in the saline water before the insertion.



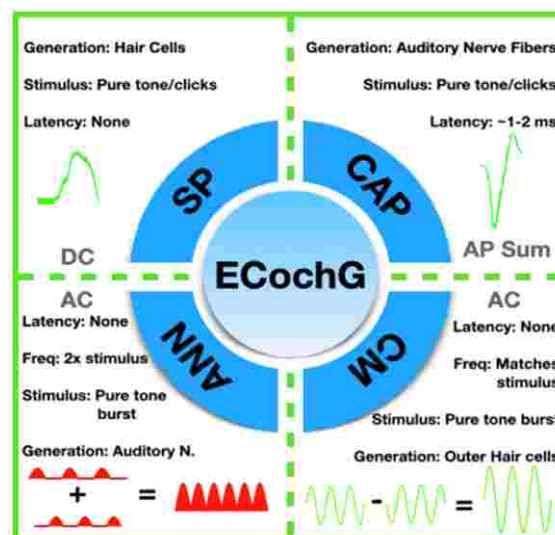
This electrode is positioned gently lateral surface of the ear drum. Electrode insertion was done through the help of Lempert speculum under microscope to avoid the dislodging of the electrode. Children and their parents were instructed about the test procedure and cooperation from the child. Initially test was started at 95dBnHL if the peak was not found than presentation level of stimulus was increased to 105 dBnHL and if responses were still not found than presentation level of stimulus increased to maximum level 115dBnHL and responses was recorded. Test was performed by a experienced audiologist. Peak identification and marking was done by two other experienced audiologist.

### ELECTROPHYSIOLOGY

ECochG measures electrophysiological responses from the cochlea and the auditory nerve. (1) During ECochG, a brief duration of acoustic stimuli (i.e. clicks or acoustic tone bursts) of alternating polarity (condensation and rarefaction) is used to elicit electrophysiological responses that can be measured using skin electrodes, extra tympanic electrodes, transtympanic electrodes, or intracochlear CI electrodes. (2) An acoustic tone burst generates electrophysiological responses from a localized region in the cochlea or the auditory nerve, whereas clicks are known to elicit responses across a broader frequency range. (2) ECochG responses can be analyzed into (1) cochlear microphonics (CM), (2) auditory nerve neurophonics (ANN), (3) summing potential (SP), and (4) compound action potential (CAP) (Fig. 1).

#### Figure 1

The four main components of ECochG. Cochlear microphonics (CM) and auditory nerve neurophonics (ANN) are alternating currents elicited from a tone burst stimuli of alternating polarity. CM represents a mechanical signal from the outer hair cells. ANN represents the phase-locked signal from the auditory nerve. The Summing Potential (SP) and the Compound Action Potential (CAP) are direct currents. SP



represents responses from all hair cells, while the CAP represents responses from the auditory nerve.

Frequency-specific alternating polarity acoustic tone bursts are used to measure CM and ANN. CM represents the difference (i.e. subtraction) between ECochG responses to the two acoustic stimuli of alternating polarity. (3) This potential is believed to primarily represent mechanical movement of the stereocilia on the outer hair cells. (4) The CM potential appears as an alternating current (AC) that is phase locked to the stimulus tone. (5) Thus, all the CM potentials recorded during ECochG provide real-time feedback. Currently, the CM appears to be the most sensitive detector of trauma during CI insertion. (6) The summation (i.e. addition) of the ECochG responses measured from two alternating polarity acoustic stimuli is known as ANN, and is believed to represent the phase locked responses of the auditory nerve. The ANN is an AC potential with a frequency response twice the stimulus frequency. (7) (8) ANN is not particularly useful for real-time feedback of trauma to the hair cells, as it is not believed to originate from intracochlear structures. The summing potential (SP) is the response of the inner hair cells at low frequencies, but can be a mixed response from all hair cells at the high

frequencies. (5) (8) The SP is a direct current (DC) signal that arises from an AC stimulus, and represents a sustained depolarization of the hair cells during sound presentation. (8) Thus, even in response to tone bursts, the SP appears only as a shift in the baseline, and does not provide immediate feedback. (9) As the SP can have multiple sources and be influenced by many factors, it is rarely analyzed in the context of real-time intraoperative recordings during CI. The compound action potential (CAP) refers to the summation of individual action potentials from the auditory nerve fibers. (8) The CAP is roughly the same potential as Wave I of an auditory brainstem response (ABR), and has identical latency as the ABR recording. (10) In patients with existing hearing loss, the CAP can be absent or highly variable, (6) and the CAP's correlation with hearing or speech testing is variable. The following inclusion and exclusion criteria were applied to all the selected subjects in the study group.

#### **Inclusion criteria**

- a) Children with bilateral severe to profound sensorineural hearing loss.
- b) Age range 1-5 yrs. (M/F)
- c) Children who have residual hearing present in ASSR.
- d) Parents consenting for study.

#### **Exclusion Criteria**

- a) Children with cochlear deformity
- b) Children with ear discharge and other ear diseases.
- c) Children who do not have any responses in ASSR.

#### **Evaluation protocol at MEHROTRA ENT HOSPITAL**

- a. Informed written consent was taken from the parents for the study and follow-ups required during the study.
- b. A detailed history and thorough physical and ENT examination was carried out.
- c. The subjects then underwent pediatric examination to rule out any neurological condition, which may hamper the child

postoperative performance. Prior to implantation a basic workup including hematological, chest X-ray, ECG (Electrocardiogram), TORCH (Toxoplasmosis, Rubella, Cytomegalovirus, Herpes simplex, and HIV) screen (if require). The general physical condition will be evaluated by Anesthetists. A specialist opinion was sought in patients with syndromic etiology of deafness. In children pre implant vaccination will be carried out.

- d. Behavioral observational audiometry (BOA), Impedance, otoacoustic emissions (OAE), Auditory brainstem response (ABR) thresholds and Auditory Steady-State Response (ASSR) was determined to evaluate the degree and type of hearing loss.
- e. Each child was subjected to undergo a high-resolution CT (computed tomography) scan and MRI (magnetic resonance imaging) scan of temporal bones.
- f. Speech perception was also assessed by SIR score before implant
- g. The child was also evaluated by a child psychologist to determine the IQ (intelligent quotient).
- h. Counseling of parents was done regarding regular follow-ups and therapy/support to the child at home. They were also made to realize the realistic expectations about the cochlear implant. Also, the parents were made to realize that they are integral part of our rehabilitation team which requires consistent hard work and patience.

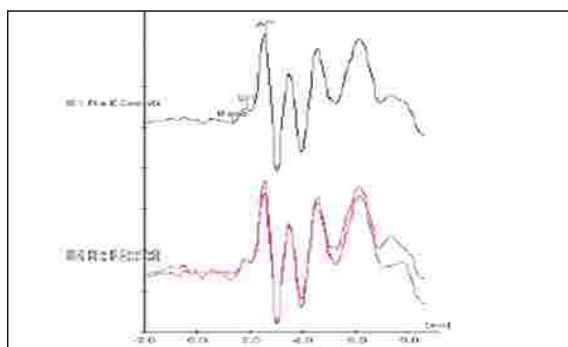
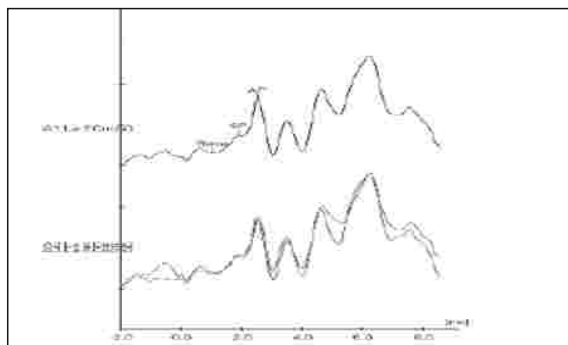
Cochlear implantation was done and the Impedance test was performed to know the status of electrode function. NEURAL RESPONSE TELEMETRY (NRT) and Electrical Compound Action Potential (E-CAP) was done in Cochlear and Medel company implant. Post operatively x ray was mandatory. Post operative ECoG test also done within 24hrs of surgery. Procedure parameters protocols were same followed as mentioned above.

## RESULTS

Pre-Implant ECochG test Results: - 40 Children who were ASSR positive participated in the study in which ECochG test responses were present in 25 children and responses were absent in 15 children. Peak and wave morphology of the ECochG test was not much clear.

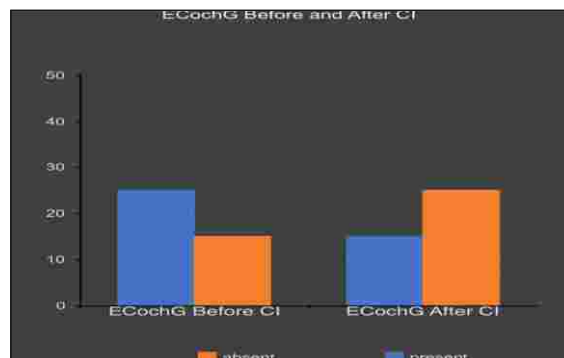
Post-Implant ECochG test Results: - 40 children who were ASSR positive participated in the study in which ECochG test responses were present in 15 children and 25 children had no responses. Peak and wave morphology of the ECochG test was not much clear.

Pre implant and Post implant electrocochleography results were compared and evaluated. Comparison was made by comparing of pre and post implant peak and wave morphology, SP/AP Area ratio and SP/AP Amplitude ratio.



## DISCUSSION

The aim of the study is to measure residual hearing in pre and post operative cochlear implant patients using electrocochleography. With the help of ASSR and ECochG test it could be



identified that residual hearing is preserved or not. ASSR test is useful in diagnosis of hearing threshold level in particular frequency region. As of now many of the studies done on ASSR testing is in threshold estimation. During ASSR testing lot of mussel's artifacts also interferes. So it must be done in an acoustic proof room under the supervision of highly qualified and experienced audiologist.

If the ASSR and ECochG responses are present before the CI surgery. It should be informed to the ENT surgeon. So the surgeon will be aware about what kind of electrode should be used and what surgical technique should be used to preserve the residual hearing.

With extracochlear recording, the recording electrode can be placed on promontory or on the tympanic membrane. Generally electrical interference is present in the operation theatre. To avoid this situation, it was planned to do the testing in proper acoustic proof room pre operatively and post operatively. So the chances of electrical interference will be minimized and the accuracy of the test results be better understood.

## ECochG and Cochlear Implantation

In the modern age of ECochG, there has been a significant shift of focus towards applications to CI. In 1985, the FDA first approved the use of multichannel CIs for adults with post-lingual deafness.(27) In 1998, Nucleus introduced the CI24M electrode array, the first capable of performing neural response telemetry (NRT).(28) Over the last two decades, the technology surrounding CI has vastly improved



---

and candidacy criteria continues to expand. Refinements in electrode design and surgical technique, including less traumatic electrode insertion, have enabled many implant recipients to maintain significant residual hearing following CI.(29)

In patients with postoperative residual hearing, combined electric and acoustic stimulation (EAS) has resulted in improved speech perception,(30) sound localization and music appreciation. Despite efforts to mitigate trauma during electrode insertion, varying degrees of hearing preservation is only achievable in 47%-82% of CI recipients. Cochlear trauma during electrode placement is assumed to be a leading cause for postoperative hearing loss. At present, it is not possible to perform high resolution temporal bone imaging in real-time during electrode placement. ECoChG, or more specifically, intraoperative CM measurements, can be used to monitor cochlear trauma during electrode placement. Over the past several years, the role and utility of intraoperative ECoChG on CI hearing preservation has become a topic of extensive debate and research. ECoChG has been used to compare pre-implantation to post-implantation responses, with the most recent advancements being made in real-time feedback during electrode insertion. The details of current knowledge on intraoperative ECoChG technique and outcomes are discussed below.

### **Intraoperative ECoChG Applications**

#### **1) ExtracochlearECoChG in CI**

With extracochlear recordings, the recording electrode can be placed on the promontory, the stapes or the tympanic membrane. In 2010, Campbell et al. made the first intraoperative extracochlearECoChG recordings in gerbils. CI electrodes were inserted under direct visualization with an endoscope to identify signs of cochlear trauma. Generally, irreversible decreases in the CM correlated visually with direct trauma to cochlear structures, and histologic analysis confirmed these changes. This study was one of the first to definitively

demonstrate that real-time changes in ECoChG potentials directly correlated to trauma, thus laying the foundation for future exploration of real-time ECoChG as a feedback tool in human CI. In humans, the feasibility of extracochlearECoChG in CI was first explored through stapes and RW recordings. In 2011, Harris and colleagues were the first to show that ECoChG potentials could be recorded from the stapes during CI. In this pilot study, insertion of the CI electrode into the basal turn of the cochlea and suctioning of perilymph was associated with loss of ECoChG signal. In 2012, Choudhury et al.(8)demonstrated that extracochlearECoChG potentials could be measured from the RW even in patients with poor preoperative audiograms and pure tone averages (PTAs) < 100 dB. The success rate of obtaining recordings varied between studies, but overall there was agreement that despite poor preoperative hearing, ECoChG waveforms could be reliably obtained in 52%-100% of patients undergoing CI.(8) Though controversial, some have speculated that pre-implantation ECoChG might serve as the most reliable predictor of postoperative speech perception compared to other commonly used clinical factors and audiological measures.

The ability for peri-implantation extracochlearECoChG to predict post-operative hearing outcomes varies among studies. Radeloff et al.(11) performed RW ECoChG in six patients, measuring CM at various time points of electrode insertion. Four patients had postoperative loss of residual hearing, despite preservation of CM thresholds during insertion.(11) Dalbert et al.(15) made measurements on the promontory pre- and post-implantation. All patients experiencing detectable threshold changes intraoperatively suffered complete loss of residual hearing, though not all with hearing loss experienced threshold changes.(15) In another cohort, none of the subjects showed a loss in post-implantation extracochlearECoChG that would suggest insertion trauma, but some still had residual hearing loss after surgery.(16) A recent study agreed that those experiencing decreases in

---

ECochG responses intraoperatively showed significantly greater likelihood of hearing loss, but hearing loss was still possible despite maintaining intraoperative extracochlearECochG thresholds.[42 The authors posited that some trauma may be limited to the high-frequency regions of the cochlea, and can be missed on routine low-frequency ECochG recordings. This discrepancy between intraoperative preservation of ECochG signal and loss of residual hearing suggests that postoperative inflammatory reactions may also play a role in hearing loss following CI. More practically, another study demonstrated that in surgeons who are given real time intraoperative ECochG feedback during electrode insertion, 85% achieved hearing preservation while only 33% of the non-feedback group did. Overall, these results suggest that real-time feedback may enable surgeons to preserve hearing in a greater number of cases. Moreover, ECochG likely provides a low sensitivity, but high specificity, when using loss of intraoperative extracochlearECochG signal as a predictor of postoperative residual hearing loss.](#)

## **2) IntracochlearECochG in CI**

The history of intracochlearECochG is somewhat limited as this technology only came to the forefront approximately 5 years ago. IntracochlearECochG has been performed by inserting a recording electrode into the cochlea or, alternatively, by using one of the CI electrodes as the recording electrode. In the most recent implementations, ECochG has been measured using the most apical CI electrode as the recording electrode and an extracochlear case, ring or ball electrode as the return electrode. In 2014, Calloway was the first to describe intracochlearECochG recordings during CI. Intracochlear responses were much larger in amplitude than extracochlear responses, as confirmed by other studies. The authors also observed increasing signal amplitudes with increasing electrode depths in the cochlea, which

they attributed to growing proximity to the residual functional neural elements at the low-frequency apex of the cochlea. Campbell was the first to prove feasibility of intracochlear recordings using the existing CI electrodes by recording from five subjects with residual hearing after CI. Dalbert et al. expanded on this technique further by performing intracochlear recordings using the CI electrode intraoperatively and postoperatively. They showed that intracochlearECochG signal could continue to decline in the first week after implantation, consistent with theories that postoperative inflammation in the cochlea may contribute to the delayed loss of residual hearing. Compared to extracochlearECochG, intracochlear measurements have been shown to have increased signal to noise ratio. However, as the electrode is constantly moving, a stable response cannot necessarily be used to detect trauma. Some authors advocate for a mixed approach with dual recording of extra and intracochlear potentials during electrode insertion, and postoperative follow up using continued intracochlear measurements.[\(16\)](#)

It is only in the last two to three years that real-time intracochlearECochG during electrode insertion has been explored. Lo et al. pioneered continuous intracochlearECochG in animal studies and showed that ECochG amplitudes tended to increase with insertion depth, with loss of signal correlating with post-implantation hearing loss. Harris and colleagues showed that it was also highly feasible in humans to continuously record CM and ANN during electrode insertion. He later characterized the intracochlearECochG amplitude patterns observed during electrode insertion into 3 types.[\(7\)](#) The Harris Type A ECochG pattern is defined as an overall increase in amplitude from the beginning of insertion to completion.[\(7\)](#) The Harris Type B pattern has maximum amplitude at the beginning of insertion, with an overall decrease as insertion goes to completion, sometimes to complete signal loss.[\(7\)](#) Finally, the Harris type C has similar amplitudes at

---

the beginning and completion of insertion, with a maximum amplitude reached mid-insertion.(7) Type A was the most common, followed by Type B, then Type C.(7) Ramos-Macias et al.(4) examined the correlation between Harris classification and postoperative hearing outcomes. Intraoperatively, the Type B pattern leading to complete loss of signal was associated with complete loss of residual hearing, and may be suggestive of irreversible trauma during insertion.(4) In the case of an intracochlear ECoChG recording that drops in amplitude but recovers, proposed mechanisms include temporary physical contact between the electrode and cochlear elements, or destructive interference between the hair cell and neural potentials.(6)

The association between loss of intracochlear ECoChG signal and cochlear trauma or electrode positioning remains controversial, and there is active debate regarding what the Harris Type B pattern represents. In Lo et al.'s animal study, histological studies showed that intraoperative loss of CAP amplitude was associated with higher grades of trauma, but not all cases of post-implantation hearing loss had signs of trauma on pathology. In humans, one retrospective case control study used post-operative imaging to identify electrode arrays that translocated into the scala vestibuli as a proxy for trauma to the basilar membrane. Similar to the animal studies, the authors found no difference in intraoperative ECoChG amplitude between the translocation group and the nontranslocation group, despite drastic differences in hearing preservation between the two groups. In contrast to these studies above, O'Connell et al. in 2017 showed that there might be a slight association between electrode translocation and intraoperative ECoChG thresholds. In their cohort, there were differences between the intraoperative ECoChG thresholds and postoperative PTA thresholds, and these differences were significantly larger for translocated electrodes. However, they were unable to demonstrate a correlation between ECoChG and postoperative behavioral

thresholds. Another study in support of this association showed that intraoperative ECoChG could reliably predict electrode translocation in 82% of patients, with a sensitivity of 100% and specificity of 77%, but only a positive predictive value of 54%. As such, the promising data presented by O'Connell et al. regarding the predictive value of intraoperative ECoChG needs further investigation, given conflicting evidence correlating ECoChG changes to postoperative outcomes.

### **Post Operative ECoChG Applications**

Postoperatively, intracochlear ECoChG has been used to determine the lowest stimulus presentation level that generates CMs or CM thresholds in CI patients with residual hearing. The results show a significant correlation between CM thresholds and behavioral thresholds in CI patients.(16) CM thresholds thus offer an objective method to assess hearing sensitivity in CI subjects who cannot participate in behavioral audiometry and can even be used to assess air-bone gaps in implanted patients. The new AIM system from Advanced Bionics allows providers to perform a quick estimation of the CM thresholds immediately after CI electrode placement, which may be helpful in understanding mechanisms driving the loss of residual hearing immediately after electrode placement.

Combined EAS has been shown to provide the best outcomes in CI, but it is important to appropriately set the frequency boundaries of acoustic and electric stimulation to further refine its efficacy. Furthermore, excitotoxicity from high levels of electrical stimulation has been shown to cause delayed postoperative hearing loss in CI patients with initially preserved residual hearing. ECoChG measurements provide an objective and time efficient method to assess EAS interaction in the cochlea and the auditory nerve. CM and ANN responses can be measured in the presence of electrical stimulation to determine the frequency boundaries of acoustic and electrical stimulation and minimize interaction between the two modes



of stimulation.

It is also worthwhile to consider the location of the CI electrodes as it determines the place-pitch sensation produced by electrical stimulation of each individual electrode. A mismatch between the frequency information delivered to the CI electrode and the place-pitch sensation produced by electrical stimulation is known to adversely affect CI outcome. CM tuning curves can be measured for different acoustic pure tone frequencies by varying the intracochlear recording electrodes and can be used to determine CI electrode location along the basilar membrane.

Thus, postoperatively, ECochG can be used to measure CM thresholds and predict behavioral auditory thresholds, determine EAS interactions, program the EAS stimulation device, and determine the cochlear location of implant electrodes, all of which may potentially lead to improvements in CI outcomes.

### Future Applications and Conclusion

ECochG offers an opportunity to measure frequency specific CMs elicited from a localized region in the cochlea. However, CMs generated for a low frequency tone such as 500 Hz may not be sensitive to cochlear trauma in the basal region during CI electrode placement. At our institution, we are using a pure tone complex to elicit CMs such that we can present up to four acoustic pure tone stimuli simultaneously and measure CMs from four different locations along the basilar membrane. Preliminary results show that these multi-frequency CM measurements can be used to monitor cochlear trauma from different regions in the cochlea.

### REFERENCES

1. Bakhos D., Marx M., Villeneuve A., Lescanne E., Kim S., Robier A. Electrophysiological exploration of hearing. *Eur Ann Otorhinolaryngol Head Neck Dis.* 2017;134:325–331.
2. Gibson W.P. The clinical uses of electrocochleography. *Front Neurosci.* 2017;11:274.
3. Santarelli R., Scimemi P., Dal Monte E., Arslan E. Cochlear microphonic potential recorded by transtympanic electrocochleography in normally-hearing and hearing-impaired ears. *Acta Otorhinolaryngol Ital.* 2006;26:78–95.
4. Ramos-Macias A., O'Leary S., Ramos-deMiguel A., Bester C., Falcon-Gonzalez J.C. Intraoperative intracochlear electrocochleography and residual hearing preservation outcomes when using two types of slim electrode arrays in cochlear implantation. *Otol Neurotol.* 2019;40(5S Suppl 1):S29–S37.
5. Fontenot T.E., Giardina C.K., Fitzpatrick D.C. A model-based approach for separating the cochlear microphonic from the auditory nerve neurophonic in the ongoing response using electrocochleography. *Front Neurosci.* 2017;11:592.
6. Giardina C.K., Brown K.D., Adunka O.F. Intracochlear electrocochleography: response patterns during cochlear implantation and hearing preservation. *Ear Hear.* 2019;40:833–848.
7. Harris M.S., Riggs W.J., Giardina C.K. Patterns seen during electrode insertion using intracochlear electrocochleography obtained directly through a cochlear implant. *Otol Neurotol.* 2017;38:1415–1420.
8. Choudhury B., Fitzpatrick D.C., Buchman C.A. Intraoperative round window recordings to acoustic stimuli from cochlear implant patients. *Otol Neurotol.* 2012;33:1507–1515.
9. Pappa A.K., Hutson K.A., Scott W.C. Hair cell and neural contributions to the cochlear summing potential. *J Neurophysiol.* 2019;121:2163–2180.
10. Minaya C., Atcherson S.R. Simultaneous extratympanic electrocochleography and auditory brainstem responses revisited. *Audiol Res.* 2015;5:105.
11. Radeloff A., Shehata-Dieler W., Scherzed A. Intraoperative monitoring using cochlear microphonics in cochlear implant patients with residual hearing. *Otol Neurotol.* 2012;33:348–354.
12. Wever E.G., Bray C.W. Auditory nerve impulses. *Science.* 1930;71:215.
13. Lempert J., Wever E.G., Lawrence M. The cochleogram and its clinical application; a

- preliminary report. *Arch Otolaryngol.* 1947;45:61–67.
14. Fromm B., Nylén C.O., Zotterman Y. Studies in the mechanism of the wever and Bray effect. *Acta Oto Laryngologica.* 1935;22:477–486.
  15. Dalbert A., Sim J.H., Gerig R., Pfiffner F., Roosli C., Huber A. Correlation of electrophysiological properties and hearing preservation in cochlear implant patients. *OtolNeurotol.* 2015;36:1172–1180.
  16. Dalbert A., Pfiffner F., Rösli C. Extra- and intra-cochlear electrocochleography in cochlear implant recipients. *Audiol Neurotol.* 2015;20:339–348.
  17. Eggermont J.J. Ups and downs in 75 years of electrocochleography. *Front SystNeurosci.* 2017;11:2.
  18. Ruben R.J., Lieberman A.T., Bordley J.E. Some observations on cochlear potentials and nerve action potentials in children. *Laryngoscope.* 1962;72:545–554.
  19. Ruben R.J., Walker A.E. The viiith nerve action potential in Meniere's disease. *Laryngoscope.* 1963;73:1456–1464.
  20. Eggermont J.J. Summating potentials in Meniere's disease. *Arch Otorhinolaryngol.* 1979;222:63–75.
  21. Schmidt P.H., Eggermont J.J., Odenthal D.W. Study of Meniere's disease by electrocochleography. *ActaOtolaryngol.* 1974;316:75–84.
  22. Gibson W.P., Moffat D.A., Ramsden R.T. Clinical electrocochleography in the diagnosis and management of Meneere's disorder. *Audiology.* 1977;16:389–401.
  23. Lamounier P., Gobbo D.A., Souza T.S., Oliveira C.A., Bahmad F., Jr. Electrocochleography for Meniere's disease: is it reliable? *Braz J Otorhinolaryngol.* 2014;80:527–532.
  24. Nguyen L.T., Harris J.P., Nguyen Q.T. Clinical utility of electrocochleography in the diagnosis and management of Meniere's disease: AOS and ANS membership survey data. *OtolNeurotol.* 2010;31:455–459.
  25. Tanaka F., Tsukasaki N., Nakao Y., Shigeno K., Kobayashi T. Electrocochleographic evaluation of hearing loss in acoustic neuromas. *Am J Otol.* 1999;20:479–483.
  26. Riggs W.J., Roche J.P., Giardina C.K. Intraoperative electrocochleographic characteristics of auditory neuropathy spectrum disorder in cochlear implant subjects. *FrontNeurosci.* 2017;11:416.
  27. Eshraghi A.A., Nazarian R., Telischi F.F., Rajguru S.M., Truy E., Gupta C. The cochlear implant: historical aspects and future prospects. *Anat Rec (Hoboken)* 2012;295:1967–1980.
  28. Shallop J.K., Facer G.W., Peterson A. Neural response telemetry with the nucleus CI24M cochlear implant. *Laryngoscope.* 1999;109:1755–1759.
  29. Carlson M.L., Driscoll C.L.W., Gifford R.H. Implications of minimizing trauma during conventional cochlear implantation. *OtolNeurotol.* 2011;32:962–968.
  30. Wolfe J., Neumann S., Schafer E., Marsh M., Wood M., Baker R.S. Potential benefits of an integrated electric-acoustic sound processor with children: a preliminary report. *J Am AcadAudiol.* 2017;28:127–140.

Copyright: © 2023 Sumit Maheshwari, et al. This is an open-access article distributed under the terms of the Creative Commons Attribution License, which permits unrestricted use, distribution, and reproduction in any medium.

#### Corresponding Author

Professor Dr. Rohit Mehrotra  
 Director, Mehrotra ENT Hospital, Harsh Nagar, Kanpur  
 E mail: [mehrotraent@rediffmail.com](mailto:mehrotraent@rediffmail.com)  
 Mob.: 8808051700

#### How to cite this article

Maheshwari S. etal; Pre And Post- Operative Electrocochleography In Cochlear Implant Cases- A Study To Preserve Residual Hearing - UPJOHNS; June 23; 11(1); page 15-24  
 DOI: <http://doi.org/10.36611/upjohns/volume11/Issue1/3>  
 Orcid Id:<https://orcid.org/0000-0003-0087-4181>



This work is licensed under a Creative Commons Attribution 4.0 International License  
 Copyright © 2020 –UPJOHNS